



**PATIENT**

Harlow Donase

**SPECIES**

Canine

**BREED**

Miniature Pinscher

**SEX**

Female Spayed

**AGE**

14 years

**WEIGHT**

12.7lbs

**INTERPRETED BY**

Maggie Machen  
Lamy, DVM  
DACVIM (Cardiology)

**IMAGING PERFORMED BY**

Pamela Harrigan,  
RDCS

**HOSPITAL NAME**

Norfolk County  
Veterinary Service

**REFERRING VET**

Dr. Richards

**INVOICE**

32122

**DATE**

8/3/23

**PRESENTING CLINICAL SIGNS**

History: Recheck echo. History chronic valvular disease- Stage B1. Currently, needs dental. BP: 111, 117, 117mmHg.

-Pertinent previous echo findings (2/3/22), LA 2.29 cm, LA:Ao 1.50, LV 2.56, borderline mildly dilated LA, moderate MR, moderate TR (2.7m/s, 29.8mmHg).

**ECHOCARDIOGRAM FINDINGS**

2D, m-mode, color flow and Doppler imaging is available.

**Left ventricle:** The LV diameter is normal with adequate myocardial function. LV wall thicknesses are normal.

**Left atrium:** The left atrium is mildly enlarged.

**Mitral valve:** The mitral valve is mildly thickened with significant prolapse into the left atrial lumen. Moderate eccentric mitral regurgitation with a normal velocity.

**Aortic valve/aorta:** The aortic valve is normal in morphology and mobility. Normal aortic outflow velocity; laminar flow. No aortic insufficiency.

**Right ventricle:** Normal right ventricular diameter and morphology indicating no overt evidence of pulmonary arterial hypertension.

**Right atrium:** Mild RA dilation.

**Tricuspid valve:** The tricuspid valve appears thickened with marked septal prolapse and moderate tricuspid regurgitation; normal velocity.

**Pulmonic valve/pulmonary artery:** The pulmonic valve is normal in morphology and mobility. No pulmonic insufficiency. Normal RVOT velocity; laminar flow.

**Pericardium/other:** No pericardial or pleural effusion noted. No obvious cardiac masses.

**Heart rhythm:** ECG reveals a sinus rhythm with an average HR of 100bpm.

**2-Dimensional Measurements**

Ao diam (cm)	1.5
LA diam (cm)	2.0
LA:Ao (Swe)	1.3
IVS thickness (cm)	0.6
LVID diastole (cm)	2.8
PW thickness (cm)	0.7
LVID systole (cm)	1.1
FS (%)	62

**Doppler Measurements**

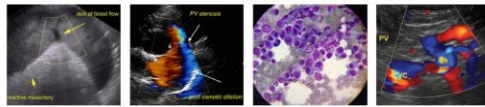
PV Vmax (m/s)	0.8
AoV Vmax (m/s)	1.2
MR Vmax (m/s)	5.7
TR Vmax (m/s)	2.7
TR PG (mmHg)	30

**INTERPRETATION OF THE FINDINGS**

Chronic degenerative valve disease causing moderate mitral and tricuspid regurgitation. Despite significant valve degeneration, a lack of significant left or right atrial enlargement indicates the current risk for complication is low. No concurrent issues such as systolic dysfunction or pulmonary hypertension are noted in this study. Assessment of progression in the future will help predict long term prognosis, which is highly variable at this stage (B1).

**RECOMMENDATIONS**

- In an asymptomatic dog without significant left atrial enlargement, no cardiac medications are clearly indicated.
- Omega fatty acid supplementation and mild salt restriction may be of some long-term benefit.



**PATIENT**

Harlow Donase

- Anesthetic risk is considered mild if needed. Cardiac protective drug choices (opioid/benzodiazepine premedication, propofol or alfaxalone induction, isoflurane gas) are recommended. Pre-oxygenate for 5-10 minutes prior to induction. Monitor for arrhythmias, hypotension, and hypoxia both intra and post-operatively and intervene as necessary. Mild IV fluid restriction is recommended to avoid fluid overload. Avoid heart rate stimulating drugs such as atropine unless clinically indicated.

**SPECIES**

Canine

**BREED**

Miniature Pinscher

- Monitor for development of a cough, labored breathing, exercise intolerance or collapse episodes.

**SEX**

Female Spayed

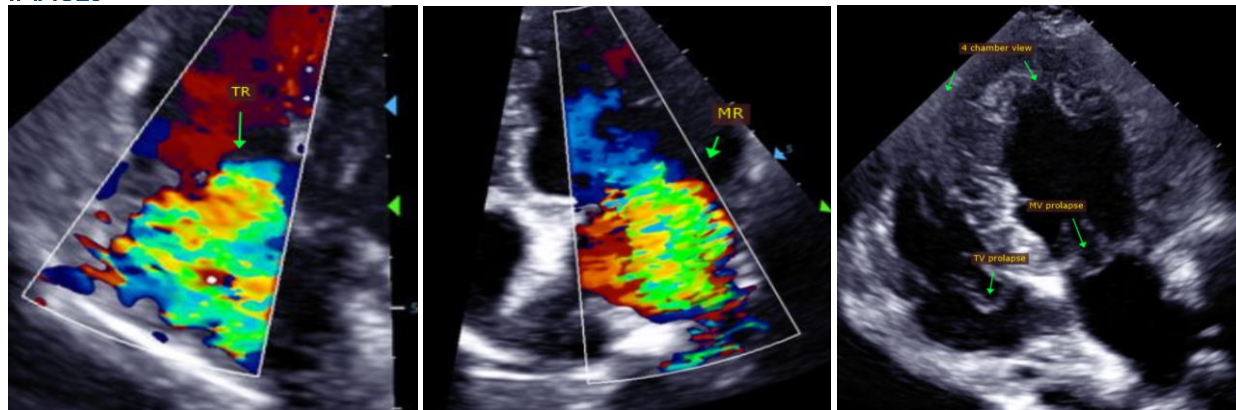
**PLAN**

- Recommend conservative monitoring with a recheck echocardiogram in 6 months, sooner if any development of clinical signs.

**AGE**

14 years

**IMAGES**



**WEIGHT**

12.7lbs

**INTERPRETED BY**

Maggie Machen Lamy, DVM  
 DACVIM (Cardiology)

The information and recommendations provided are based on the images presented by the referring veterinarian. No evaluation can be communicated regarding pathology that was not visible in the image/video clips provided.

**IMAGING PERFORMED BY**

Pamela Harrigan, RDCS

Thank you for this referral. This report was generated using transcription software, and minor dictation errors may be present. If the clinical or image interpretation does not parallel your findings or if I can be of any further assistance, please contact me.

**HOSPITAL NAME**

Norfolk County Veterinary Service

Maggie Machen Lamy, DVM  
 Diplomate of the American College of Veterinary Internal Medicine (Cardiology)  
 info@sonopath.com

**REFERRING VET**

Dr. Richards

Echocardiogram performed by: Pamela Harrigan, RDCS  
 Pet Animal Ultrasound Service ([4paus.com](http://4paus.com))

**INVOICE**

32122

**DATE**

8/3/23